



HISTOLOGICAL STUDY OF THE EFFECT OF ACETAMINOPHEN DRUG ON THE KIDNEYS OF MALE ALBINO RATS

Zainab Salah Abdulgabar, Maysoon Khudair AL- Hadrawi*, Rajaa Jawad Mohamed

Department of Medical Laboratory Techniques, Technical Institute /Kufa Al-Furat Al-Awsat Technical University,
31003 Al Kufa, Iraq.

Article Received: 20 August 2023 | Article Revised: 08 September 2023 | Article Accepted: 04 October 2023

Corresponding Author: Maysoon Khudair AL- Hadrawi

Department of Medical Laboratory Techniques, Technical Institute/ Kufa Al-Furat Al-Awsat Technical University, 31003 Al Kufa, Iraq.

Email ID: kin.msn@atu.edu.iq

ABSTRACT

The study was performed in the animal house of the College of Education, for a period (21/11/2021- 12/12/2021) to evaluate the histological changes in the kidney of a male albino rat, treated with acetaminophen (450mg/kg). The study lasted two months by following (20) male rats and was (16-20) weeks weighted between (200-250g) they divided into two groups each consisting of ten males. The first group was orally given the tap water and it was the control group. The second group treated and it was orally with acetaminophen at (450 mg/kg) Five rats from each group were then left to be fed with water and diet for two weeks after the last treatment in order to monitor the progress of clinical signs, histological and macroscopic changes. Hematoxylin and Eosin stained images showed that acetaminophen overdose induced acute kidney injury as demonstrated by widening of glomeruli space (Bowman space), tubular dilatation, numerous cellular debris in the renal tubules with tubular epithelial degeneration, and vacuolization. The pathological changes were observed in the histological section of kidneys that dosed ((acetaminophen) such as cellular change in the glomeruli cells, the epithelium of was disrupted and increased connective tissue. From this study, It was concluded that acetaminophen drug has negative effects in the cells of the kidneys tissue, For long term. Despite the fact that widespread use of acetaminophen it made histopathological changes in the kidneys. These findings revealed nephrotoxicity was associated with an increase in oxidative damage and apoptosis.

KEYWORDS: Acetaminophen, Nephrotoxicity, albino rats.

INTRODUCTION

Acetaminophen is a drug on the World Health Organization's List of Essential Medicines. It is widely used in our environment. It is a highly effective analgesic and antipyretic and is safe due to few negative effects when given in correct doses. It has spread increasingly in North America since the early 1980s.^[1] Now the most widely used in the United States with more than 28 billion doses distributed annually It is available on the counter in many doses

including 325gm, 500g, and 650gm tablets or capsules respectively It is an ingredient in many combinations products including combination analgesics With opiate products as well as other available products such as cough syrup.^[2]

Despite its frequent use and circulation all over the world, the mechanism by which it relieves pain is not fully understood, as it was previously believed that acetaminophen does not inhibit the synthesis of Prostaglandin, although pharmacological and toxicological effects indicate this, but research conducted in the past two decades, indicated Acetaminophen is usually effective for pain associated with mild to moderate inflammation such as sprains and contusions, but not in patients with acute inflammation such as rheumatoid arthritis or acute gout.^[3] The explanation for this process is the indirect inhibition of cyclooxygenase enzymes by inhibiting the peroxidase binding site, thus reducing the activity at the cyclooxygenase site. It seems that the analgesic effects of acetaminophen are in the form of peripheral and central mechanisms. Peripheral is the indirect inhibition of cyclooxygenase, while the central effects are believed to be mediated by modulating downstream pain-inhibiting pathways.^[4] It is available without a prescription it is the drug of choice in patients who cannot be treated with non-steroidal anti-inflammatory drugs (NSAID) Such as people with bronchial asthma, hemophilia, children -Pregnant or breastfeeding women The mechanism is complex and includes the effects of the both peripheral (cox inhibition) and central (cox serotonergic descending neuronal pathway).^[5] The long-lasting administration of paracetamol affects blood pressure and may cause higher blood pressure and increased prevalence of heart infarction.^[6] Due to the increasing problem of the safety of acetaminophen, the validity of the drug without a prescription for a long time is questioned, and this indicates that it is not a magic drug that is free from side effects, especially when taken regularly and in large doses.^[7] So the current study was designed to clarify the histological effect of frequent and long-term use of acetaminophen in adult male rats, as these changes persisted despite stopping the dosing for a period of two weeks after the last acetaminophen treatment

Laboratory Animals

The use of male albino rat animals by 20 rats with age (16- 20) weeks and with an average weight (200 -250) g. They were left for acclimatization in the animal house of the College of Education before the start of the study after housing them in a cage with good ventilation and access to Feed and water throughout the experiment.

Histological Study

Kidney specimens were immediately fixed in 10 % formal saline for 24 hours. Paraffin blocks were prepared, and 5 µm thick sections were subjected to hematoxylin and eosin (H&E) stain to elucidate the status of kidney architecture and the structural changes For histopathological study and light microscopic examination. A histopathologist evaluated kidney sections and recorded the observations. The acetaminophen-treated groups that showed definite histopathological abnormalities in the kidney were selected for comparison with non-treated rats.

Groups of Study

The animals were divided into (2) groups, 10 animals each

Group (1): Served as control, dosed with distilled water from the first day of the experiment, which was sacrificed during periods of 21 days.

Group (2): (acetaminophen-treated group) It included 10 white male rats orally dosed With acetaminophen 450 mg/kg for 4 weeks. (18), which was sacrificed during a period of 21 days. Five rats from each group were then left to be fed with water and diet for two weeks after the last treatment with acetaminophen.

RESULTS

The kidney was Examined by a light microscope showed the funding gland extended In the control group, the structure of the kidney, the glomerulus appeared normal in size and shape, and the tubule membrane.^[1,7]

The histological study of the kidney showed that aggregation of the inflammatory cell in the cortex and medulla with interstitial blood hemorrhage and a certain number of glomeruli and damaged glomeruli, the proximal and distal convoluted tubules were degeneration. As in figures.^[3,2,4,5]

Group By the light microscope the surface of the epithelium of the cortex showed a focal area of the disruption with distortion and shrinkage of the cells of glomeruli and marked cellular infiltration of Fatty infiltration with fat cells (A) lymphocytic infiltration cell figure (6).

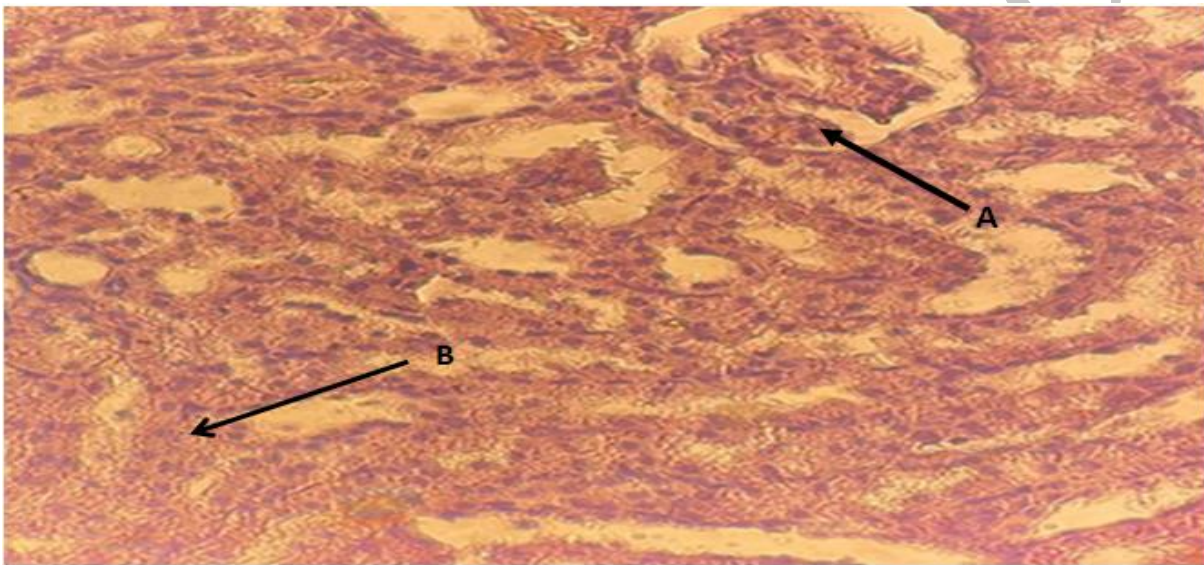


Figure 1: Histological section in the kidney I of a rat from the control group showing: a normal capsule of the renal glomeruli in the cortex area (A), a normal renal glomeruli in the cortex (B) (Hematoxylin and Eosin 400).

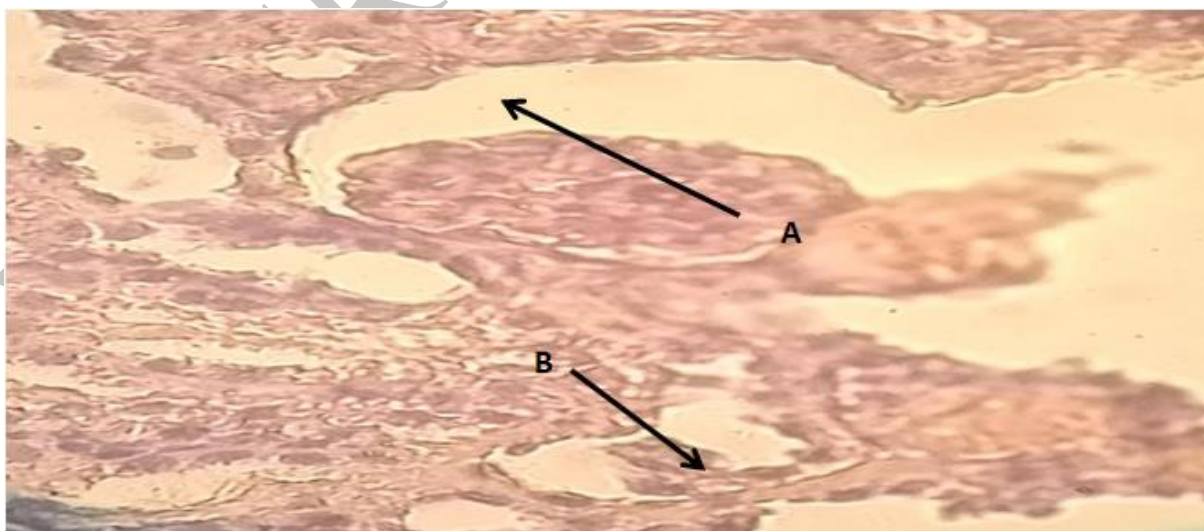


Figure 2: Histological section in the kidney cortex of a rat from the acetaminophen group showing: Contraction of the renal glomerulus (A) Necrosis of the epithelium lining the renal tubule within the cortex area (B) (Hematoxylin and Eosin 400).

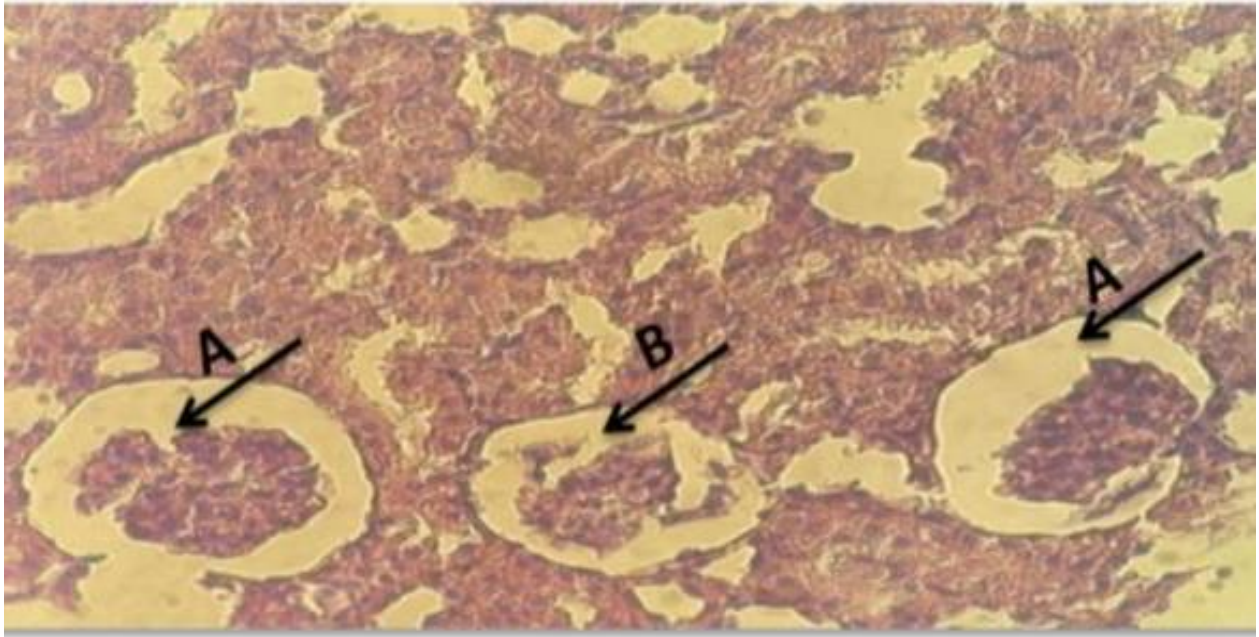


Figure 3: Histological section of kidney in treatment group showing: A amplitude of bowman's space B Glomerular cells necrosis and shrinkage Hematoxylin and Eosin 400).

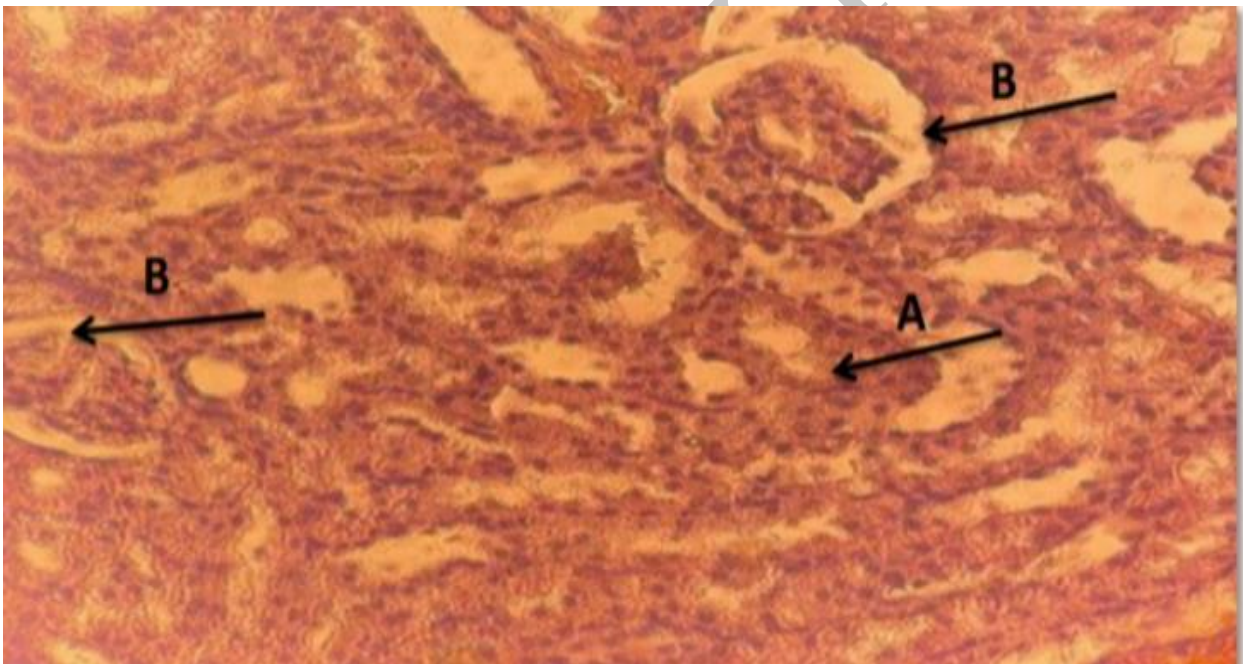


Figure 4: A histological section in the kidney of rat from the acetaminophen group showing: infiltration of inflammatory cells densely around the renal glomerulus), complete damage to the renal glomerulus in the cortex area (B (Hematoxylin and Eosin 400).

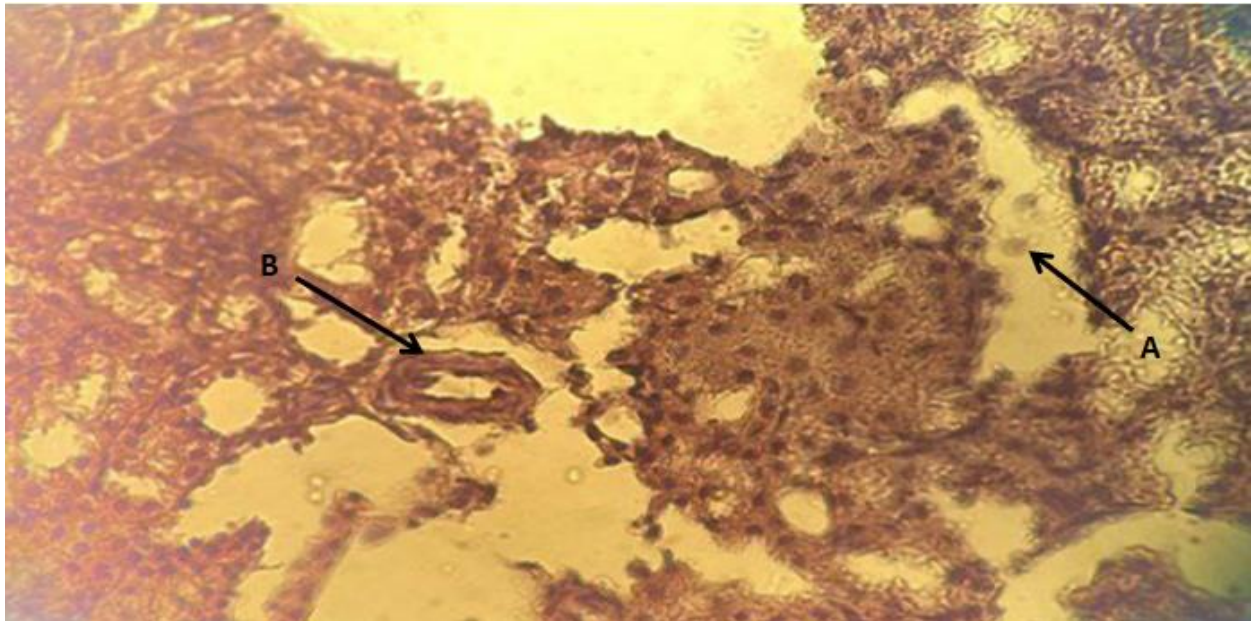


Figure 5: Histological section of kidney in treatment group showing: renal cortex with multiple tubules, (A) (proximal convoluted tubules vacuolization in renal epithelial cell (B) Hematoxylin and Eosin 400).

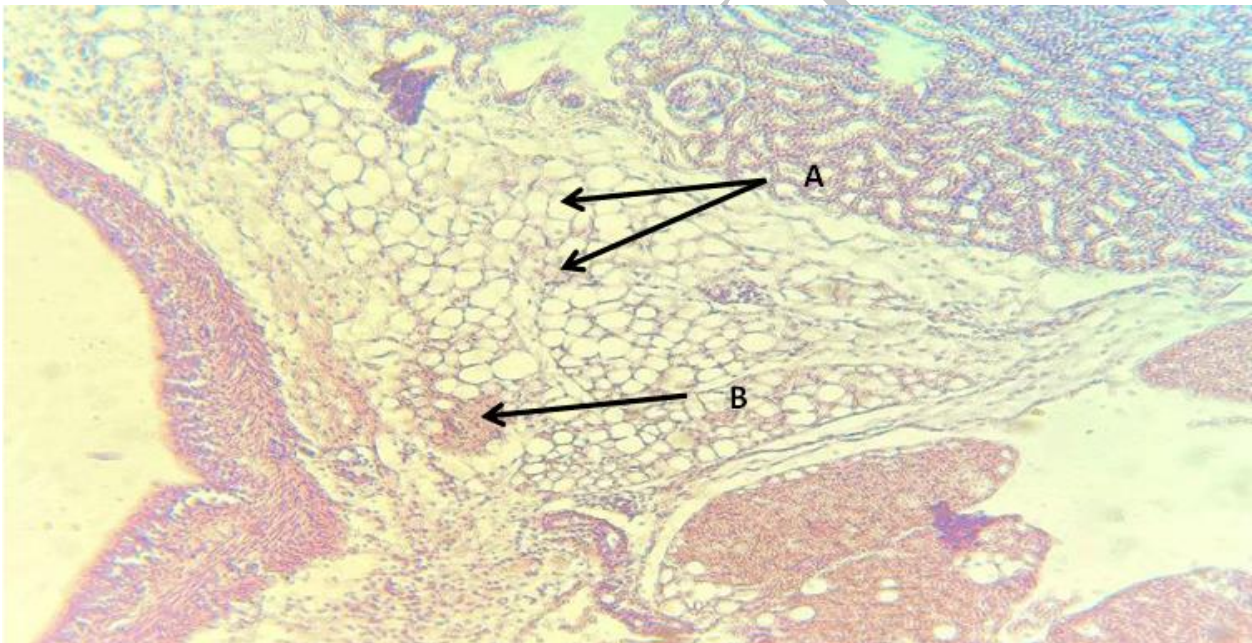


Figure 6: Histological section of kidney in the rats after two weeks of stopping the dosage of acetaminophen showing: Fatty infiltration with fat cells(A) lymphocytic infiltration suggesting in inflammatory response(B) (Hematoxylin and Eosin 100).

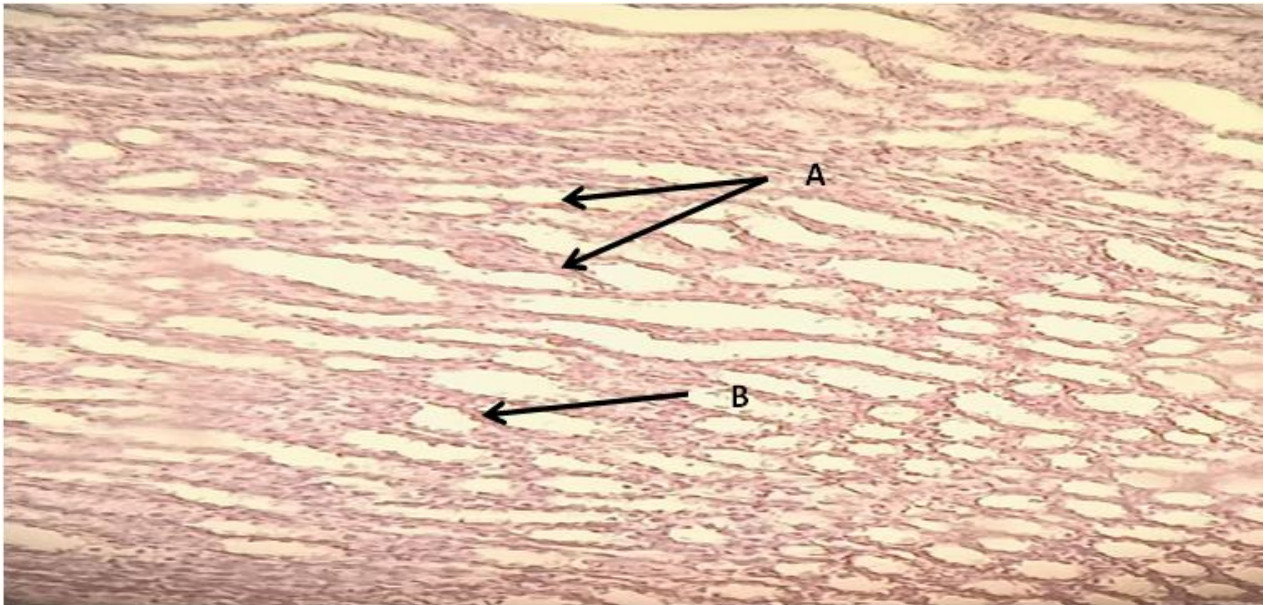


Figure 7: Histological section in the kidney rat from control group shows: renal tubules with normal cells(A)convoluted tubules normal cuboidal cells (B) Hematoxylin and Eosin 100.

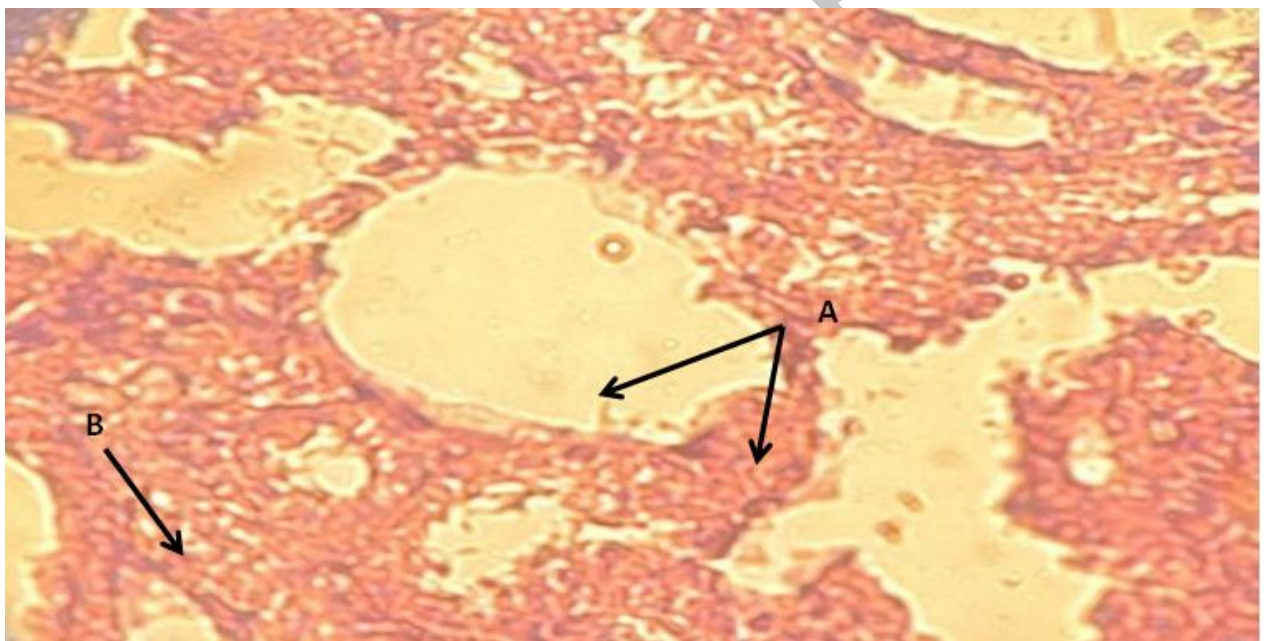


Figure 8: Histological section in the kidney rat from treatment I group shows: infiltration of inflammatory cells densely around the renal glomerulus (A), complete damage to the renal glomerulus in the cortex area (B) (Hematoxylin and Eosin 100).

DISCUSSION

In this study, acetaminophen-induced histological changes in rats like hyperplasia in epithelial glomerular cells of kidney histopathological changes caused by the effect of acetaminophen drug. This result agreed with many authors who reported that acetaminophen had an effective role in improving the various changes induced in other organ^[10] in this work. In agreement with^[9] reported the same results; they stated that exposure of epithelial cells to oxidant stress leads to an elevation in nitric oxide release and nitrite production and a decrease in cell viability. Nitric oxide has a role

in acute renal failure because of its free radical nature; through its reaction with the superoxide radical^[11], it probably generates the very cytotoxic peroxynitrite that could damage the tubular epithelium cells. We conclude that a long-term use of Paracetamol might cause histological changes in the kidney, which could probably lead to renal insufficiency or impairment after using, as evidenced in the photomicrographs of the kidney section cells as well as prominent congestion of blood vessels also the acetaminophen may impair the antioxidant defense system leading to oxidative damage by changing the balance between oxidant and antioxidant factors.^[13] Also, the congestion and dilatation of blood vessels were seen these results agreed with.^[14]

The present study showed that treatment with acetaminophen stimulated histopathological changes for long-term of used in the albino rat. The results of this study reveal that the functional anatomical relationship between is important for the development of surgical research in human and veterinary medicine^[15] found no significant pathological changes in the liver tissue. Whereas, images demonstrated substantial kidney damage induced by acetaminophen). Their treatment protocol (1 g/ kg) of acetaminophen could be the reason for such differences.^[16] In the present work, examination of kidney sections treated with paracetamol revealed also marked inflammatory cell infiltration. These results were in agreement with^[17] the effects of the oxidative enzymes and decreased levels of antioxidant enzymes in the blood when acetaminophen was given in high doses to rats leading to an increase in reactive oxygen species and oxidative stress. Oxidative stress will cause degeneration and desquamation in renal tissue.^[18] It was reported that paracetamol toxicity caused glutathione diminution and ultimately lipid peroxidation and starts its intracellular accumulation where its reactive metabolite, Nacetyl-p-benzoquinone imine (NAPQI), after making a covalent bond with renal tissues, causes deterioration and death of cells which in turn is associated with electrolyte imbalance and creatinine and blood urea nitrogen instabilities.^[19]

CONCLUSION

Acetaminophen made histopathological changes in the rat's kidney. These findings revealed that this nephrotoxicity was associated with an increase in oxidative damage and apoptosis. Our findings pointed out the risk of renal damage due to long-term use of Acetaminophen although these drugs are reported to be effective in pain management, their toxic effects must be kept in mind during chronic usage. Renal function monitoring is recommended.

REFERENCES

1. Peruzzi, L., Gianoglio, B., Porcellini, M. G., Copper, R., Neonatal end – stage renal failure associated with maternal ingestion of cyclooxygenase – type – 1 selective inhibitor, nimesulide as tocolytic. *The Lancet*, 1999; 354: 1615.
2. Balasubramaniam, J., Nimesulide and neonatal renal failure. *The Lancet*, 2000; 335: 575.
3. Acute renal failure due to acetaminophen ingestion: a case report and review of the literature. *Journal of the American Society of Nephrology*, 6: 48-53.
4. Pathan, M. M., Khan, M. A., Moregaonkar, S. D., Somkuwar, A. P. and Gaikwad, N. Z., Amelioration of paracetamol induced nephrotoxicity by *Maytenus emarginata* in male Wistar rats. *International Journal of Pharmacy and Pharmaceutical Sciences*, 2013; 5: 471-474.
5. Sheen, C. L., Dillon, J. F., Bateman, D. N., Simpson, K. J. and Macdonald, T.M., Paracetamol toxicity: epidemiology, prevention and costs to healthcare system. *Quartely Journal of Medicine*, 2002; 95: 609-619.

6. Rowden AK, Norvell J, Eldridge DL, Kirk MA. Updates on acetaminophen toxicity. *Med Clin North Am*, 2005; 89: 1145-1159.
7. Karaali, H. F.; Fahmi, R. R. & Borjac, J. M. Effect of *Ocimum basilicum* leaves extract on acetaminophen-induced nephrotoxicity in BALB/c mice. *J. Complement. Integr. Med.*, 2018; 16(2). Doi: 10.1515/jcim2018-0111.
8. Kitada, M. & Koya, D. Renal protective effects of resveratrol. *Oxid. Med. Cell. LKandemir, F. M., Kucukler, S., Caglayan, C., Gur, C., Batil, * A. * A. * and * Gülçin, * İ. **; Therapeutic effects of silymarin and naringin on methotrexate-induced nephrotoxicity in rats: Biochemical evaluation of anti-inflammatory, antiapoptotic, and autophagic properties. *Journal of food biochemistry*, 2017; 41(5) ongev., 2013: 568093.
9. Yousef, M. I., Omar, S. A. M.; El-Guendi, M. I. and Abdelmegid, L. A., Potential protective effects of quercetin and curcumin on paracetamol-induced histological changes, oxidative stress, impaired liver and kidney functions and hepatotoxicity in rat. *Food and Chemical Toxicology*, 2010; 48: 3246–3261.
10. Baker J, Silverton RE and Pillister CJ, Dehydration, impregnation, embedding technique and section preparation. *Introduction to Medical Laboratory Technology*, 7th edition, 2000; 199–242.
11. Borne RF. Nonsteroidal Anti-inflammatory Agents. In: Foye's Principles of Medicinal Chemistry 6th Edition, Williams DA, Lemke TL, Lippincott Williams & Wilkins Philadelphia, 2007; 751-793.
12. Gotsman, I., Zwas D, Planer D, Admon D, Lotan C, Keren A., The significance of serum urea and renal function in patients with heart failure. *Medicine (Baltimore)*, 2010; 89: 197-203.
13. Premila Abraham., Oxidative Stress in paracetamol induced Pathogenesis (1). I damage. *Indian Journal of Biochemistry and Biophysics*, 2005; 42; 95-62 Renal.
14. Ghosh, J., J. Das, P. Manna and P.C. Sil, Acetaminophen induced renal injury via oxidative stress and TNF-alpha production: therapeutic potential of arjunolic acid. *Toxicology*, 2010; 268: 8-18.
15. Madhukiran P, Ganga Rao B, Invitro evaluation for free radical scavenging activity of methanolic leaf extract of *Cyathea gigantea* (wall Ex.hook). *Int J Pharm Res Dev*, 2011; 3(2): 509.
16. Mesembe, O. E., Igiri, A. O., Naikot, I., Ekam, V. S., Odukana, J. F., and Fischer, V. A., Liver and Kidney Morphologies Following Vitamin E Supplementation During Caffeinated and Non – Caffeinated Paracetamol Administration in Rats. *J. Exp. & Clin. Anat*, 2004; 3(1): 35 – 38.
17. Bosch, M. E., Sanchez, A.J. R., Rojas, F. S. and Ojeda, C. B., Determination of paracetamol: Historical evolution. *Journal of Pharmaceutical and Biomedical Analysis*, 2006; 42: 291–321.
18. Canayakin, D., Bayir, Y., Kilic Baygutalp, N., Sezen Karaoglan, E., Atmaca, H. T., Kocak Ozgeris, F. B., Keles, M. S. and Halici, Z., Paracetamol-induced nephrotoxicity and oxidative stress in rats: the protective role of *Nigella sativa*. *Pharmaceutical biology*, 2016; 54(10): 2082-2091.
19. Bancroft, J. and Gamble, M., *Theory and Practice of Histological Techniques* 6th edition. Churchill Livingstone. New York, Edinburgh, London, 2008; 83-92.