

Ebola virus: A global public health frightening

Khitam F. Abbas¹, Layla Saleh Abdul-Hassan², Sama S. Abd Al_Ameer³, Taghreed F. Almahbobi⁴, Ameer S. Alkhayyat⁵, Hujran Abdulaheem Abed⁶, Oday Mitib Hadi⁷, Baraa Akeel Al-Hasan⁸, Maryam. R. Mansor⁹, Estabraq Hassan Badder Al-Muhanna¹⁰

^{1,3,5,8,9,10}Medical Laboratory Technology Department, College of Medical Technology, The Islamic university, Najaf, Iraq.

²Community Health Department, College of Health and Medical Techniques/Kufa/Al-Forat Al-Awsat Technical university.

⁴Jaber Ibn Hayyan Medical University, Iraq.

⁶Department of Medical Laboratory Techniques, College of Health and Medical Techniques, University of AlKafeel, Najaf, Iraq

⁷Medical Laboratory Techniques Department, College of Health and Medical Techniques/Kufa/ Al-Forat Al-Awsat Technical university.

Abstract

Ebola virus causes disease, previously known as the hemorrhagic fever, is a menace routinely lethal sickness triggered by infection per the Filoviridae family's Ebola virus. The Ebola virus (EBOV) is feasted by commerce by means of the blood or bodily fluids of someone who has contracted or died from EVD, as well as contaminated things like as needles, animals that was infected, otherwise bush meat. EVD takes two days to three weeks' incubation period then an rushed inception devoid of the need for a carrier status. A flu-like syndrome is characterized by a rapid onset of high fever, chills, and myalgia, among other clinical signs. It's generally identified by a combination of clinical symptoms, including start of disease, high fevers lasting fewer than 3 weeks, and as a minimum 2 hemorrhagic symptoms in spite of no predisposing causes. This is usually enough evidence for physicians to suspect EHF and start supportive therapy until test findings confirm the virus. Patients first show with nonspecific influenza similar symptoms before succumbing to shock and several organ failures. severe bleeding problems and several organ failures are the leading causes of death. For the reason that there is presently not any conventional rehabilitation for EVD, this one is perilous to minimize contagion and the virus's transmission. Supportive treatment for patients includes maintaining fluid balance, electrolyte balance, hypertension, and oximetry, beside that treatment consequences arise after secondary infections. This review gives a comprehensive summary of the Ebola virus.

Keywords: Ebola virus disease; Ebola hemorrhagic fever; diagnosis; treatment.

INTRODUCTION

A severe infectious outbreak characterized by acute viral hemorrhagic fever first emerged in 1976. Because this outbreak in Yambuku had 318 cases and an 88 % mortality rate (280 deaths), it was called Ebola then subsequently Ebola River, which was discovered wherever the Democratic Republic of Congo (DRC) [1]. Besides the genus Marburg virus, the Ebola virus belonging to family Filoviridae. The envelope of this extremely pathogenic virus has a filamentous or branching convoluted structure and contains a linear RNA genome non-segmented single-stranded negative-sense [2]. This virus comes in five distinct species, each with its own set of biological properties and pathogenicity [2, 3], as shown in figure (1).

The original source of the Ebola virus is unknown to this day, but this is thought to be animal-borne because infected animals transmit the virus directly to other animals, such as monkeys, chimps, and apes, and even humans, leading to Ebola virus distributed throughout the human species via human-to-human disease transmission [4]. Fruit bats, which belong to the Pteropodidae family, seem assumed to be the likely source for Ebola viruses (EBOV), with humans and the rest mammals reflect as occasional accidental hosts [5].

Address for correspondence: Khitam F. Abbas,
College of Medical Technology, The Islamic university, Najaf, Iraq.

Access this article online

Quick Response Code:



Website:

www.pnrjournal.com

DOI:

10.47750/pnr.2022.13.03.115

This is an open access journal, and articles are distributed under the terms of the Creative Commons Attribution-NonCommercial-ShareAlike 4.0 License, which allows others to remix, tweak, and build upon the work non-commercially, as long as appropriate credit is given and the new creations are licensed under the identical terms.

For reprints contact: pnrjournal@gmail.com

How to cite this article: Khitam F. Abbas, Dr. Layla Saleh Abdul-Hassan, Sama S. Abd Al_Ameer, Taghreed F. Almahbobi, Ameer S. Alkhayyat, Hujran Abdulaheem Abed, Oday Mitib Hadi, Baraa Akeel Al-Hasan, Maryam. R. Mansor, Estabraq Hassan Badder Al-Muhanna, Ebola virus: A global public health frightening, J PHARM NEGATIVE RESULTS 2022;13:766-768.

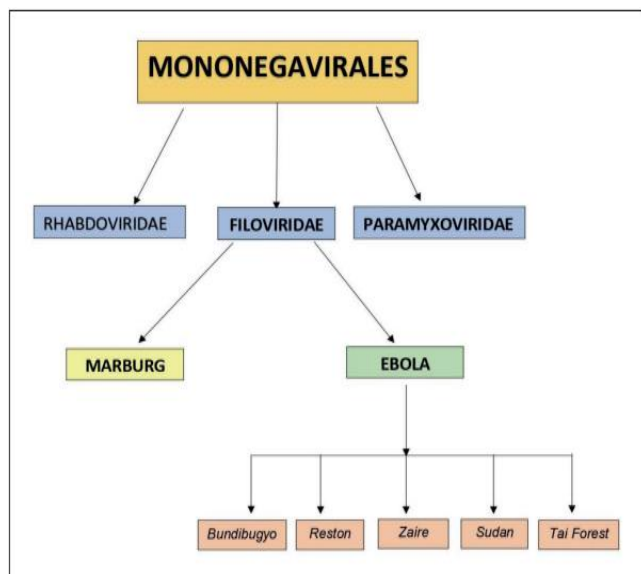


Figure 1 - Classification of Ebola Virus

The outbreak of Ebola originated inside West Africa in a rural place in south-eastern of Guinea between 2014 and 2016. In the interior weeks, this one be obligatory extent to metropolitan areas and across borders, and within months, the aforementioned must come to be an international pandemic [4]. This epidemic was the start of the West African Ebola pandemic, and it was also the biggest outbreak of Ebola virus that recorded [6].

From 2014 to 2016, the West African (EVD) outbreak caused at least 28,616 cases and 11,310 mortalities [7]. In previous Ebola virus epidemics, case treatment has mostly centered proceeding by segregating patients infected with EVD, avoidance infection and governor protocols, besides varying levels of rudimentary loyal upkeep [8]. EVD was managed with increasingly supplementary unconventional supportive cure aimed at patients throughout the West African pandemic [9,10,11]. Mortality was over 74 percent at the start of the outbreak [12], although it later dropped to 31–37 percent [13, 14], possibly owing to better prompt case revealing and supportive dealing. In West Africa, specific medication against Ebola virus be situated merely accessible in rare cases. Patients who were evacuated to European as well as American hospitals and got intensive care plus anti-Ebola virus therapies, on the other hand, had a fatality rate of 18.5% [9, 15,16,17,18,19].

Clinical manifestations

EVD is a kind of intense hemorrhagic fever with 2 to 21 days for symptoms to appear (mean 4-10) with that are similar to the respiratory tract infection, such as high temperature, chills, malaise, and muscle aches. The hot condition possibly will be modest for primary infection stages; on the other hand, it can quickly worsen with chills in addition to rigors [20]. Fever with just a skin rash mostly on face, neck, chest, and artileries, generally developing afterwards 5-7 days of

sickness, lethargy, vomiting, diarrhea, as well as anorexia are the most often document symptoms in the existing outbreak in Africa. [21,22].

Diagnosis

At the time of clinical manifestation, leukopenia with lymphocytes and a higher proportion of granulocytes typically frequent laboratory results. Leukocytosis can develop as the illness advances, also an upsurge in undeveloped granulocytes. A long-term condition that lasts till death is Thrombocytopenia. Alanine as well as aspartate aminotransferase (ALT, AST) serum levels are commonly found to be somewhat increased [20]. In the early stages of the disease, blood total bilirubin levels are either normal or increased, and jaundice is uncommon. Severe fluid loss through diarrhea and vomiting beside that lack of sufficient water replacement results in elevated serum urea nitrogen and creatinine levels [23].

To confirm infection, enzyme-linked immunosorbent assay (ELISA), as well as molecular test such polymerase chain reaction (PCR), and viral isolation techniques are utilized [20].

Treatment

Symptomatic as well as helpful therapy as electrolyte standby, dietary maintenance, preserving oxygen prominence and blood pressure upkeep, and handling superfluous infections, remain the chief measures ordered to infected individuals. In attendance is definitely not authorized EVD vaccination or conventional therapy that has been tested in people [24, 25]. ZMapp is a pharmacological drug for EVD that is still in the early phases of consideration. It includes three "humanized" monoclonal antibodies (mAbs) against the EBOV GP protein. Nicotiana, in particular, is a kind of plant benthamiana, generate these antibodies [26]. This medicine was initially tested in people in an experimental setting for the duration of the 2014 West African EVD pandemic, nonetheless never randomized organized study has been conducted to assess if it works or if it is secure enough to have already commercialized [27, 28].

Inmazed (REGN-EB3), unlike ZMapp, would be the first FDA-approved therapy for children and adults with EVD [29]. Atoltivimab, maftivimab, and odesivimab are the three completely monoclonal antibodies (mAbs) for human that make up REGN-EB3. These three mAbs in the REGN-EB3 combination won't be competing for binding to the glycoprotein (GP) of Ebola virus, but instead attach to the GP at separate sites at the same time, resulting in strong viral neutralization [30,31]. The envelope protein GP of the Zaire ebolavirus facilitates virus attachment and membrane fusion with cell membranes of host cell. The antibodies will attack the GP protein expressed on the virus-infected host cell and destroy the virus by antibody-dependent cellular cytotoxicity. [31]. Ebanga would be monoclonal antibody for human that

is used to cure the ebola virus from Zaire. Fever, tachycardia, diarrhea, vomiting, hypotension, tachypnea, and chills are the most prevalent side effects linked with Ebanga, compared to serious side effects related with ZMapp as well as Inmazeb [32].

Conclusion

EVD is a highly contagious illness that has caused a number of epidemics, mostly in Africa. The specific origins of the Ebola virus remains unknown to this day, however it is thought to be animal-borne since sick animals transmit the virus directly to other animals. For EVD, there are currently just a few medicines and therapy options. In addition to supportive care, the most regularly utilized medications include ZMapp, Inmazeb, and Ebanga. The mortality rate in patients treated with Inmazeb, is lowered by 17%. Inmazeb is the preferable medication in terms of efficacy. Ebanga is an optimal in patients suffer cardiovascular complications.

REFERENCES

1. Report of an International Commission. Ebola haemorrhagic fever in Zaire, 1976. *Bull World Health Organ.* 1978; 56 (2), 271-93.
2. H. Feldmann, T.W. Geisbert. Ebola haemorrhagic fever. *Lancet.* 2012; 377 (9768), 849-62.
3. J.H. Kuhn, S. Becker, H. Ebihara, et al. Proposal for a revised taxonomy of the family Filoviridae: classification, names of taxa and viruses, and virus abbreviations. *Arch Virol.* 2010; 155 (12), 2083-2103.
4. Centers for Disease Control and Prevention. 2014–2016 Ebola Outbreak in West Africa. (accessed on 28 December 2020).
5. Leroy EM, Kumulungui B, Pourrut X, et al. Fruit bats as reservoirs of Ebola virus. *Nature.* 2005; 438 (7068), 575-6.
6. Centers for Disease Control and Prevention. History of Ebola outbreaks. (accessed on 28 December 2020).
7. World Health Organization: Situation Report. Ebola Virus Disease. 10 June 2016. 2017.
8. Feldmann H, Geisbert TW. Ebola haemorrhagic fever. *Lancet.* 2011;377(9768):849–62.
9. Leligdowicz A, Fischer WA 2nd, Uyeki TM, Fletcher TE, Adhikari NK, Portella G, Lamontagne F, Clement C, Jacob ST, Rubinson L, et al. Ebola virus disease and critical illness. *Crit Care.* 2016;20(1):217.
10. Langer M, Checcarelli E, Gottardello D, Giovannella E, Monti G, Rossi N, Scaccabarozzi G, Sisillo E, Turella M, Tagliabue P, et al. Con EMERGENCY contro Ebola in Sierra Leone [Italian]. *Ricerca e Pratica.* 2015;31(2):61–9.
11. Hunt L, Lee JS. Empiric intravenous fluid and electrolyte therapy in patients with Ebola virus disease. *Trop Dr.* 2016;46(3):148–50.
12. Schieffelin JS, Shaffer JG, Goba A, Gbakie M, Gire SK, Colubri A, Sealfon RS, Kanneh L, Moigboi A, Momoh M, et al. Clinical illness and outcomes in patients with Ebola in Sierra Leone. *N Engl J Med.* 2014;371(22):2092–100.
13. Ansumana R, Jacobsen KH, Sahr F, Idris M, Bangura H, Boie-Jalloh M, Lamin JM, Sesay S. Ebola in Freetown area, Sierra Leone--a case study of 581 patients. *N Engl J Med.* 2015;372(6):587–8.
14. Hunt L, Gupta-Wright A, Simms V, Tamba F, Knott V, Tamba K, Heisenberg-Mansaray S, Tamba E, Sheriff A, Conteh S, et al. Clinical presentation, biochemical, and haematological parameters and their association with outcome in patients with Ebola virus disease: an observational cohort study. *Lancet Infect Dis.* 2015;15(11):1292–9.
15. Kreuels B, Wichmann D, Emmerich P, Schmidt-Chanasit J, de Heer G, Kluge S, Sow A, Renne T, Gunther S, Lohse AW, et al. A case of severe Ebola virus infection complicated by gram-negative septicemia. *N Engl J Med.* 2014;371(25):2394–401.
16. Wolf T, Kann G, Becker S, Stephan C, Brodt HR, de Leuw P, Grunewald T, Vogl T, Kempf VA, Keppler OT, et al. Severe Ebola virus disease with vascular leakage and multiorgan failure: treatment of a patient in intensive care. *Lancet.* 2015;385(9976):1428–35.
17. Sueblinvong V, Johnson DW, Weinstein GL, Connor MJ Jr, Crozier I, Liddell AM, Franch HA, Wall BR, Kalil AC, Feldman M, et al. Critical Care for Multiple Organ Failure Secondary to Ebola virus disease in the United States. *Crit Care Med.* 2015;43(10):2066–75.
18. Johnson DW, Sullivan JN, Piquette CA, Hewlett AL, Bailey KL, Smith PW, Kalil AC, Lisco SJ. Lessons learned: critical care management of patients with Ebola in the United States. *Crit Care Med.* 2015;43(6):1157–64.
19. Connor MJ Jr, Kraft C, Mehta AK, Varkey JB, Lyon GM, Crozier I, Stroher U, Ribner BS, Franch HA. Successful delivery of RRT in Ebola virus disease. *J Am Soc Nephrol.* 2015;26(1):31–7.
20. Ayten Kadanali, Gul Karagoz. An overview of Ebola virus disease. *North Clin Istanbul* 2015;2(1):81-86.
21. Kortepeter MG, Bausch DG, Bray M. Basic clinical and laboratory features of filoviral hemorrhagic fever. *J Infect Dis* 2011;204 Suppl 3:810-6.
22. West TE, von Saint André-von Arnim A. Clinical presentation and management of severe Ebola virus disease. *Ann Am Thorac Soc* 2014; 11:1341-50.
23. Joffe S. Evaluating novel therapies during the Ebola epidemic. *JAMA* 2014; 312:1299-300.
24. Kanapathipillai R, Henao Restrepo AM, Fast P, Wood D, Dye C, Kieny MP, et al. Ebola vaccine--an urgent international priority. *N Engl J Med* 2014; 371:2249-51.
25. Butler D. Ebola drug trials set to begin amid crisis. *Nature* 2014; 513:13-4.
26. Centers for Disease Control and Prevention. Ebola virus disease Information for Clinicians in U.S. Healthcare Settings.
27. Bacon J, Owens M. Infected Dallas nurse ID'd; gets transfusion from Ebola survivor. 2014. Oct 28, [Last accessed on 2014 Oct 28].
28. Nagata T, Lefor AK, Hasegawa M, Ishii M. Favipiravir: a new medication for the ebola virus disease pandemic. *Disaster Med Public Health Prep* 2015; 9:79-81.
29. US Food and Drug Administration. Drug Trials Snapshots: INMAZEB. (accessed on 25 January 2021).
30. Markham A. REGN-EB3: first approval. *Drugs* 2021;81(1):175–8.
31. Highlights of Prescribing Information. INMAZEB. Regeneron Pharmaceuticals Inc. New York. 2020. (revised October 2020; accessed 24 January 2021).
32. US Food and Drug Administration. FDA Approves Treatment for Ebola Virus